

## ACUTE KIDNEY INJURY PRECIPITATED BY HAFF DISEASE IN A 28-YEAR-OLD NIGERIAN MALE “CASE REPORT”

V. Ogala-Akogwu<sup>1,2</sup>, P. Uduagbamen<sup>3</sup>, H. Galadanci<sup>2</sup>, E. Anteyi<sup>2</sup>

1. Department of Medicine, State House Medical Centre, Abuja, Nigeria
2. Department of Medicine, National Hospital, Abuja, Nigeria.
3. Department of Internal Medicine, Bowen University/Bowen University Teaching Hospital, Ogbomosho, Nigeria.

### Correspondence:

**Dr. P. Uduagbamen**

Department of Medicine,  
Bowen University Teaching Hospital,  
Ogbomosho, Nigeria.  
Email: petr.uduagbamen@gmail.com

Submission Date: 3rd Feb., 2024

Date of Acceptance: 30th May, 2024

Publication Date: 30th Aug., 2024

### ABSTRACT

Haff disease is defined as unexplained rhabdomyolysis following ingestion of some sea fish and crayfish. First reported in 1926 from the Baltic region, its pathophysiologic mechanism is largely unknown, but toxins release have been implicated. Common features include generalized myalgia, brown/dark urine, elevated serum creatine kinase and creatinine, kidney dysfunction can be severe enough to cause acute kidney injury (AKI).

We present the case of a 28-year-old man who ate cooked freshwater fish and initially presented with diffuse myalgia, headache and brown-colored urine, and later fever and diarrhea. He had severely elevated serum creatine kinase and creatinine, and was managed as a case of Haff disease related AKI (HDR-AKI) complicated by sepsis. He had haemodialysis and antibiotics, and recovered kidney function. A detailed history of recent diet and occupational exposure is essential in the diagnosis and management of HDR-AKI. Dialysis could be life-saving.

**Keywords:** Fresh water fish, Haff disease, Rhabdomyolysis, Acute kidney failure, Haemodialysis, Creatine kinase, Myalgia.

### INTRODUCTION

Haff disease, defined as unexplained rhabdomyolysis following ingestion of some sea fish and crayfish.<sup>1</sup> It was first reported in the Baltic region in 1924, then from the former Soviet Union, and United States<sup>2</sup>, among others. Organ enlargement is rare but early deaths have been reported in the few case fatalities.<sup>2</sup> Acute kidney injury (AKI) can complicate rhabdomyolysis of whatever cause.<sup>3</sup> Pathophysiologic mechanisms for AKI include ischemic tubular necrosis, direct toxicity and tubular obstruction.<sup>4</sup> Renal replacement therapy (RRT) may be required for kidney function restoration.<sup>4</sup> We present the first case of Haff disease in Nigeria and Africa and the first association with AKI, requiring RRT (haemodialysis).

**Case profile:** A 28-year-old digital analyst presented with a week history of generalized myalgia and diarrhea, 4 days of low grade fever, and 3 days of oliguria, and altered sensorium. He took a meal of cooked freshwater fish the night preceding the onset of symptoms. He had vomiting with six episodes that lasted for 2 days and this was followed by the passage of loose watery stool. He self-administered Metronidazole and Ibuprofen, and had at a peripheral facility, antimalarial and Ceftriaxone. He had no history of ingesting herbal remedies. His urine became darker, the volume progressively became smaller and he developed altered sensorium. He had no prior risk

for kidney disease, and neither smoked nor took alcohol.

He was restless, confused, jaundiced, afebrile but pale. He had tachycardia, tachypnea, but blood pressure (BP) was 110/60 mmHg. He had vague abdominal tenderness but no organ enlargement.

We made an assessment of acute kidney injury (AKI) precipitated by sepsis, to rule out nephrotoxicities.

On further questioning, patient gave more detailed information concerning the ingested fish and the timing (within 24 hours incubation period). This raised the probability of Haff disease and, drugs induced toxic nephropathy).

Labs showed proteinuria ++, haematuria +++, no nitrites. Serum biochemistry (Table 1) at presentation showed severe renal and hepatic dysfunction. Blood and urine culture yielded no growth, Serology for Hepatitis B and C and HIV were negative.

**Definitive diagnosis:** Acute kidney injury precipitated by Haff disease

He had saline rehydration, Ceftriaxone 1g daily, and the first dialysis session via a femoral catheter. He regained consciousness but daily urine output remained

**Table 1:** Serial biochemistry result

TESTS	Normal	Adm	5DOA	2WOA	3WOA	4WOA	5WOA
Bicarbonate	22-30	11	-	-	-	21-	-22
Sodium, mmol/L	135-150	128	128	138	138	138	133
Potassium, mmol/L	3.5-5.5	4.9	4.9	3.7	4.4	4.4	3.5
Corrected calcium, mmol/L	2.10-2.55	1.40	-	-	-1.5	1.8	2.7
Phosphate, mmol/L	0.87-1.45	3.48	3.6	1.97	-	2.69	-1.8
Urea, mmol/L	2.5-6.4	13.5	19.8	12.0	20.1	32.1	13
Creatinine, $\mu$ mol/L	50-106	505	714	437	575	656	175
Creatine kinase, U/L	55-170	8657		8457	3074	1203	687
Uric Acid, mmol/L	3.5-7.2	17.2	17.2	7.3	9.6		
AST, IU/L	<38	1335				53	44
ALT, IU/L	<41	6360			1632	48	12
ALP, IU/L	<129				225	192	152
GGT, IU/L	<66	95				672	
Total Bil, $\mu$ mol/L	<17.1	50				42	
Conj bilirubin, $\mu$ mol/L	<7	34				22	76
Proteins, g/L	60-80					47	52
Albumin, g/L	35-50	22			29	29	28
Haemoglobin, g/dL	13-17.5	11	11.6	10.7	10.0	10.1	11.5
MCV, fl	76-96	81					82
MCH, g/dL	27-30						27
MCHC, g/dL	31-35						33
WBC, $\times 10^3$ /L	4-10.5	3.8	4.9	15.8			7.8
Platelets, $\times 10^9$ /L	150-400	75	68	318	215	198	245
ESR, mmhr	0-7	75	70				24
Neutrophils, %	45-65	62		79		75	69.8
Lymphocytes, %	25-45	34		18		11.8	20.3
Monocytes, %	2-10	2				10.5	6.4
Eosinophils, %	1-6	2				1.4	1.7

DOA-days on admission, WOA-weeks on admission, AST-aspartate transaminase, ALT-alanine transaminase, ALP-alkaline phosphatase, GGT-gamma glutamyl transferase, MCV-mean corpuscular volume, MCH-mean corpuscular haemoglobin, MCHC-mean corpuscular haemoglobin concentration, WBC-white blood cell, ESR-erythrocyte sedimentation rate

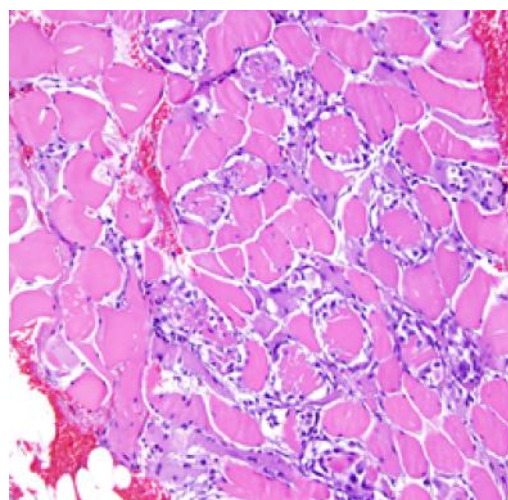
$\leq 50$ ml. Ceftriaxone was changed to Meropenem 500 mg twice daily, on the fifth day on admission (5DOA) on account of high grade fever and rising white cell count (WCC). The clotting profile was normal all through admission. His LFT began to improve from the third week on admission (3WOA). Further laboratory results (Table 1) are shown below. Abdominal ultrasound scan showed no organ disease. A renal biopsy was done on account of persistent oliguria, and histology (figure 1) showed 14 acutely shrunken glomeruli, acute tubular necrosis, granular and flaky tubular casts, calcified, non-atrophic tubules, few inflammatory cells, with preserved vascular integrity.

**Histological diagnosis:** Rhabdomyolysis with myoglobinuria.

An internal jugular vein catheter (IJVC) was used to replace the femoral catheter.

At 5WOA, his urine output increased to 400mls, the IJVC was removed, and he was discharged. At his

first follow up visit, he was clinically stable, his daily urine output ranged 1.5-2.0 L.



**Figure 1:** photomicrogram showing acute tubular necrosis, shrunken glomeruli, without tubular atrophy in a 28year-old man with Haff disease.

## DISCUSSION

Haff disease arises from kidney-related complications which result from the destruction, with loss of integrity, of skeletal muscles and release of intracellular metabolites and toxins into the extracellular fluid.<sup>4</sup> Rhabdomyolysis, as a precipitant of Haff disease could present in mild, moderate, severe or life-threatening disease with severe AKI with or without disseminated intravascular coagulation (DIC).<sup>2</sup> AKI complicates about 40% cases of rhabdomyolysis, and mortality could be up to 8%.<sup>5,6</sup> Despite the high risk of AKI in rhabdomyolysis, Haff disease is known to be a very rare condition, with only 26 cases reported in the United States in thirty years. This, coupled with the fact that trauma, crush injuries, sepsis, and high voltage electrical injury could cause rhabdomyolysis-precipitated AKI, the very high serum concentration of creatine kinase (CK) and the “within-24-hours” (mean incubation period of 8 hours) interval between fresh fish ingestion and symptom manifestation, is highly suggestive of Haff disease.<sup>5,6</sup>

Though, the type of fish ingested by the index patient was not ascertained, the fact that many of the implicated fishes (from previous studies) such as fresh water crayfish, freshwater, and saltwater salmon are also eaten in Nigeria, further strengthened our belief that the index patient had Haff disease.<sup>6</sup> Rare non-physical causes include electrolyte imbalances, and metabolic disorders and a very rare cause of rhabdomyolysis is Haff disease.<sup>2,4</sup> The possibility of a non-steroidal anti-inflammatory drug (NSAID)-induced kidney disease secondary to Ibuprofen (documented to be more nephrotoxic than Diclofenac), particularly in association with stressors like dehydration and fever.<sup>7</sup> This was ruled out on account of the kidney-related symptoms that preceded Ibuprofen use. Moreover, the index patient had eaten some fish the preceding night and developed symptoms hours later.

Pathologic mechanisms involved in Haff disease include tubular toxicity, ischaemic necrosis and obstruction.<sup>5-6,8</sup> Fluid extravasation with plasma depletion can activate the sympathetic vasoconstrictor pathway, leading to concentrated myoglobin (a tubular toxin), which can combine with Tamm-Horsfall proteins (acidic urine) forming distal tubular casts which can obstruct tubular flow.<sup>9</sup> Rhabdomyolysis could present with hyperkalemia, hypocalcaemia, elevated liver enzymes, pigmented granular cast, absence of red cells, and markedly elevated CK, as were found in index patient.<sup>9</sup> The severely elevated CK in the index case (8657 U/L) could increase the risk for AKI, as it has been documented that CK of 1000-2500 IU/L (5-10

times the upper limit of normal) is associated with a heightened risk for AKI.<sup>10</sup>

AKI complicating Rhabdomyolysis often present in the initial stages with volume depletion hence aggressive fluid replacement, (at times 10-12L daily) is required.<sup>2,10</sup> Mannitol and bicarbonate, sometimes used to induce diuresis, and urine alkalinization respectively, are of unproven benefit.<sup>11,13</sup> Severe AKI (stage 3) associated with severe (refractory) hyperkalemia, volume overload or acidosis is an indication for dialysis, for rapid and efficient correction of fluid, blood pressure and electrolyte derangement.<sup>13</sup> The persistent oliguria despite the haemodialysis treatment raises the possibility of acute cortical necrosis (progression from severe acute tubular necrosis), a condition that could be dialysis dependent.<sup>14</sup> The long duration of hospital stay (days) also attest to the severity of the AKI coupled with the persistent oliguria, a condition that implicates a prolonged maintenance phase (stage) of AKI with loss of polarity between the basolateral and apical tubular membranes.<sup>13-14</sup> The index case emphasizes the fact that the duration and response to treatment of AKI varies and could be dependent on several interrelated factors.

Though, the baseline kidney function parameters in the index case were not known, the fact that he had no antecedent risk factor for kidney disease, a serum creatinine greater than six times of normal met the AKI stage 3 (severe) diagnostic criteria.<sup>14</sup> The ingestion of sea fishes hours before the onset of symptoms is highly suggestive of Haff disease. The haematological indices at presentation, the prolonged and severe illness tended to justify a super-imposed septic course complicating Haff disease. The initial absence of leucopenia (viral) or leukocytosis with neutrophilia (bacterial, or rarely fungi) in the patient is unlikely of a septic cause hence our conclusion that symptomatology was Haff disease-induced. This therefore warranted the high index of suspicion that clinched the diagnosis, and for optimal management.

**Conclusion:** Haff disease is an AKI complicating rhabdomyolysis that results from ingestion of freshwater fishes can further be complicated by sepsis thereby worsening the outcome. Prompt diagnosis aided by a detailed recent dietary history, with prompt rehydration, and dialysis (when needed) are effective management strategies. Disease severity and prognostication is related to the serum CPK concentrations. Though the condition is quite rare, an enlightenment programme to discourage people from ingesting the implicated fishes could be a worthwhile endeavour.

## REFERENCES

1. **Huang C**, Peng L, Gong N, *et al.* A Retrospective Analysis of Crayfish-Related Rhabdomyolysis (Haff Disease). *Emerg Med Int.* 2019; 2019: 4209745.
2. **Buchholz U**, Mouzin E, Dickey R, *et al.* Haff disease: from the Baltic Sea to the U.S. shore. *Emerg Infect Dis.* 2000; 6(2):192-195.
3. **Feng G**, Luo Q, Zhuang P, *et al.* Haff disease complicated by multiple organ failure after crayfish consumption: a case study. *Rev Bras Ter Intensiva.* 2014; 26(4):407-409.
4. **Ko A**, Song J, Golovko G, *et al.* Higher risk of acute kidney injury and death with rhabdomyolysis in severely burned patients. *Surgery.* 2022; 171(5): 1412-1416.
5. **Patel DR**, Gyamfi R, Torres A. Exertional rhabdomyolysis and acute kidney injury. *Phys Sportsmed.* 2009; 37:71–79.
6. **Diaz J.** Don't be Half-Educated About Haff Disease in Louisiana. *J L State Med Soc.* 2015; 167(1): 6-10 PMID: 25978748
7. **Uduagbamen PK**, Salako BL, Hamzat MA, *et al.* Kidney Function in Frequent Users of Non-steroidal anti-inflammatory Drugs (NSAIDs). *Open J Int Med* 2020; 10(1): 69-82
8. **Torres PA**, Helmstetter JA, Kaye AM, Kaye AD. Rhabdomyolysis: pathogenesis, diagnosis, and treatment. *Ochsner J.* 2015; 15:58–69
9. **Samuel HU**, Balasubramaniyan T, Thirumavalavan S, *et al.* Rhabdomyolysis with myoglobin-induced acute kidney injury: A case series of four cases. *Indian J Pathol Microbiol.* 2021; 64(2):382-384.
10. **Stewart IJ**, Cotant CL, Tilley MA, *et al.* Association of rhabdomyolysis with renal outcomes and mortality in burn patients. *J Burn Care Res.* 2013; 34:318–325.
11. **Yang B**, Xu J, Xu F, *et al.* Intravascular administration of mannitol for acute kidney injury prevention: a systematic review and meta-analysis. *PLoS One.* 2014; 14; 9(1):e85029.
12. **Hewitt J**, Uniacke M, Hansi NK, *et al.* Sodium bicarbonate supplements for treating acute kidney injury. *Cochrane Database Syst Rev.* 2012; 2012(6): CD009204.
13. **Subashri M**, Sujit S, Thirumalvalavan K, Poongodi A, Srinivasaprasad ND, Edwin Fernando M. Rhabdomyolysis-associated Acute Kidney Injury. *Indian J Nephrol.* 2023; 33(2):114-118.
14. **Prakash J**, Singh VP. Changing picture of renal cortical necrosis in acute kidney injury in developing country. *World J Nephrol.* 2015;4(5):480-6.